

PROPOSED GUIDELINES

Based on frequencies found in literature review

Major Features

- ◆ Dysphagia / Feeding difficulty / Gastrostomy tube (g-tube) (95%)
- ◆ Postnatal short stature (97%)
- ◆ Characteristic facial features (98%)
- ◆ Thick lips (95%)
- ◆ Loose skin (94%)
- ◆ Abnormal palmar skin creases (99%)
- ◆ DD (developmental delay) / MR (mental retardation) (100%)

Unique Features

- * Congenital heart problems (65%) including pulmonic stenosis (20%), hypertrophic cardiomyopathy (40%) and atrial tachycardia (30%)
- * Benign (44%) and malignant tumors (16%)
- * Characteristic facial features with large mouth (78%)
- ◆ Stretchy skin with hyperpigmentation
- ◆ Kyphoscoliosis
- ◆ Engaging personality
- ◆ Curly hair
- ◆ Normal head circumference

Other Features

- ◆ Polyhydramnios (62%)
- ◆ Birth weight >50%
- ◆ Hernias (50%)
- ◆ Vision problems - ptosis and strabismus

- * When added to Major Features will greatly increase the specificity of diagnosis

Costello Syndrome Diagnostic Guidelines

Defining the criteria to diagnose a multiple congenital anomaly syndrome takes many years, many patients and remains largely unscientific, often relying on the “gestalt” (overall impression) of a syndrome to make the final diagnosis.

Costello's first reports in 1971 and 1977 were expanded by der Kaloustian (1991), and Martin and Jones (1991). Recent review articles characterize over 100 patients (Hennekam, 2003), and summarize neurological and behavioral issues (Kawame et al., 2003; Axelrad et al., 2004, Delrue et al., 2003), cardiac complications (Lin et al., 2002), orthopedic problems (Yassir et al., 2003), malignancies (Gripp et al, 2003), and the adult appearance (White et al., 2005).

A clinical diagnosis of Costello syndrome can now be confirmed by testing for specific mutations in the H-ras gene.

For additional information or copies of this brochure contact:

Lisa Schoyer, Parent
taos@earthlink.net

V. K. Proud, Medical Geneticist
vproud@chkd.org

WEB LINKS:

Online Mendelian Inheritance in Man:
<http://www.ncbi.nlm.nih.gov/entrez/dispmim.cgi?id=218040>

International Costello Syndrome Support Group:
www.costellokids.org.uk

Thanks to Angela Lin , MD, and Karen Gripp, MD,
Co-Directors, Costello Syndrome Professional Advisory Board

© 2005 by Virginia Proud and CSFN
You are free to copy this document without changes - for noncommercial use only.

122205

Costello Syndrome



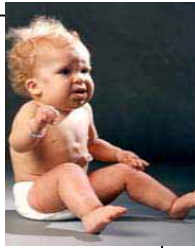Guidelines for Clinical Diagnosis

Clinical Geneticists have been working for the past 10 years with families and the International Costello Syndrome Support Group (ICSSG) and the Costello Syndrome Family Network (CSFN) to better understand this disorder. For the 4th International Costello Syndrome Conference in St. Louis, Missouri, we presented diagnostic guidelines for Costello syndrome.

NATURAL HISTORY

Infants (<1 year)

Polyhydramnios
 Fetal distress
 C-section (Cesarean section)
 LGA (large for gestational age)
 Feeding problems and hypotonia
 Gastrostomy tube (g-tube) in the first 4 years
 FTT (failure to thrive)
 Growth delay in weight and length but with normal head circumference
 Motor delays



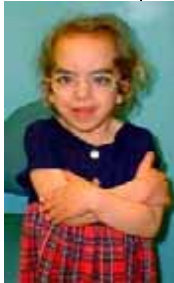Toddlers (1-3 years)

Distinctive facial features, broad mouth
 Loose, lax skin, soft, deep wrinkles, abnormal creases in palms and soles, stretchy skin, loose joints
 Hernias
 Hypertrophic cardiomyopathy
 Arrhythmia, especially atrial tachycardia
 Strabismus, ptosis
 Malignancy
 DD (developmental delay)



Children (4-12 years)

Short stature
 Distinctive facial features with broad mouth and thick lips
 Kyphoscoliosis, cervical kyphosis
 Remarkably pleasant, sociable, humorous and easy-going personality



Adolescents/Adults

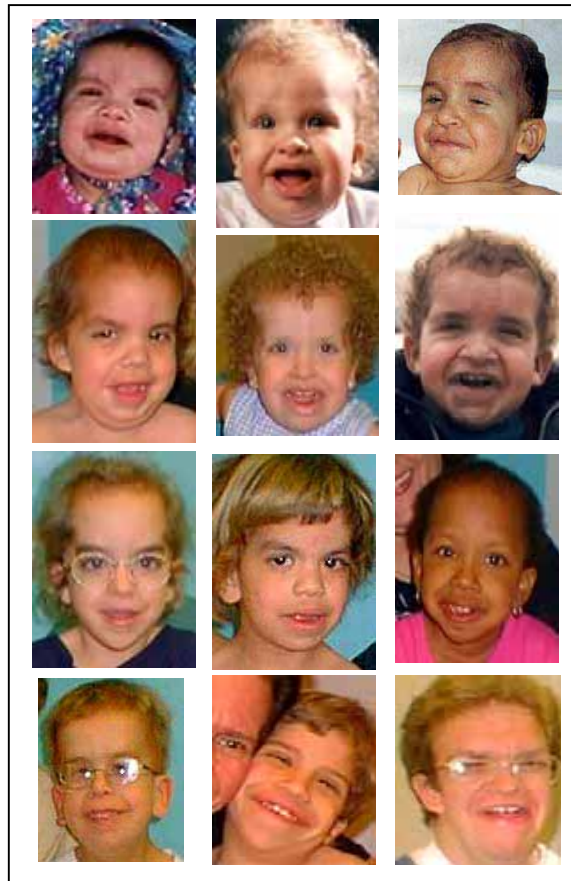
Coarse classic facial features
 Thicker, often curly hair
 Nasal fibromata
 Breast papilloma
 Hyperkeratosis, hyperpigmentation
 Short stature
 Skeletal and orthopedic problems
 DD (developmental delay) / MR (mental retardation)



KEY FEATURES

The faces of these individuals, who range in age from infancy to adulthood, illustrate the distinctive appearance of Costello syndrome.

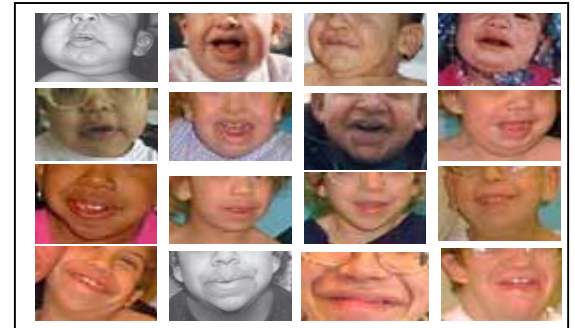
Distinctive facial features



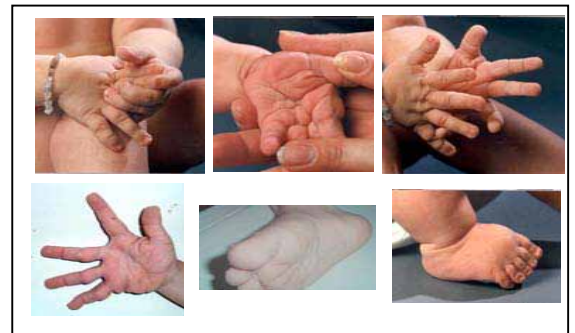KEY FEATURES

continued

Large mouth and thick lips



Loose skin / deep creases



Life-threatening complications

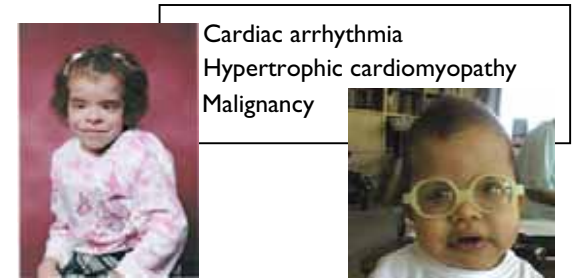


Photo credits go to the parents of the above children and adults and, for the fourth image on the first panel, Rick Guidotti/Positive Exposure.